

## Is Therapeutic Ultrasound Efficient in Treating Peyronie's Disease?– Case Report

Nataša Kos<sup>1</sup>, Marko Brčar<sup>2</sup>

<sup>1</sup>Assistant Professor, Head Of Medical Rehabilitation Unit, University Medical Centre Ljubljana, Slovenia

<sup>2</sup>Physiotherapist, Medical Rehabilitation Unit, University Medical Centre Ljubljana, Slovenia

---

**Abstract:** Peyronie's disease is a disease that affects men. We do not know its cause and the treatment differs. Often invasive treatment such as infiltration of hard tissue in the penis or operative treatment is mentioned. Ultrasound therapy is a non-invasive method where we aim, by using ultrasound waves, to break apart the hard non-elastic tissue that grows in the penis and causes both pain and penile curvature during erection.

In the article we present the case of patient with Peyronie's disease where ultrasound therapy was used.

**Keywords:** Peyronie's disease, therapeutic ultrasound, erectile dysfunction

---

### I. Introduction

Peyronie's disease is an acquired penile abnormality which is characterised by the scarring and fibrosis of connective tissue of the tunica albuginea.<sup>1</sup> It affects between three to nine percent of men.<sup>2</sup> Pathophysiology is not clear, the most commonly mentioned cause is microvascular trauma in the erectile or semi-erectile state in the connection with sexual activity. <sup>1</sup>Fibrous plaque causes pain usually during erection, sexual dysfunction and penile deformity. <sup>3</sup> Men experience emotional distress; they are anxious in sexual situations and less confident in sexual intercourse. □ Sometimes the depression occur, almost 54% of the men with Peyronie's disease have problems with interpersonal relationships. □

The diagnosis of Peyronie's disease is based upon careful history and clinical examination of the genitalia. The diagnostic ultrasound is recommended in the literature for evaluation and measurement of plaque size as diagnostic procedure and also for following the results of the treatment. <sup>6</sup> With that said, we can use for evaluating the effectiveness of the treatment different questionnaires, which describe the influence of the disease on patient's life, among them the most frequently mentioned is International Index of Erectile function 5 (IIEF 5).<sup>7</sup>

Urological International questionnaire of erectile function consists of 15 questions and was developed to monitor the effectiveness of treatment for etiologically different erectile dysfunctions and is also translated to the Slovenian language. <sup>9, 10</sup> A shorter 5 question version is more appropriate for patients, is considered a good diagnostic tool for evaluating erectile dysfunction and is used throughout the world in clinical practice. <sup>11</sup> The IIEF - 5 questionnaire consists of five questions and for each answer a number of points is given. The score is the sum of the responses to the five items, so that overall score may range from 1 to 25. <sup>12</sup> A score of 20 or higher indicates a normal degree of erectile functioning. <sup>12</sup>

The management of Peyronie disease is controversial and there is no gold standard treatment. American Association published the guidelines to provide the clinical framework for the diagnosis and treatment of Peyronie's disease. <sup>1</sup>In this guideline we can't find data about usefulness of the therapeutic ultrasound. Even by reviewing the existing literature we failed to find a case where only ultrasound therapy was used. We only found a study evaluating the effectiveness of an ultrasound and laser combination therapy. <sup>8</sup>

### II. Patient treatment protocol and case report

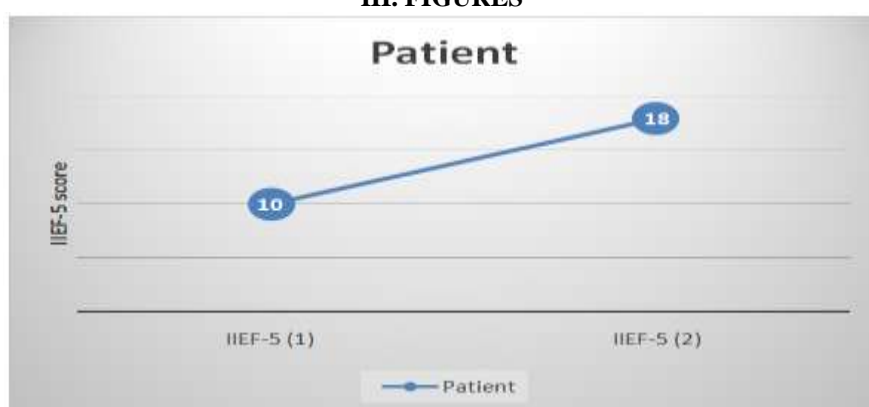The patient was referred to treatment by an urologist. He was examined by a specialist of physical and rehabilitation medicine. A detailed medical history was obtained (age, symptom duration, curvature size, pain presence, additional diseases and treatment already received) as well as an exam performed.

Before the treatment started we also performed a diagnostic ultrasound and the patient filled out the International Index of Erectile Function (IIEF-5). We used a continuous 3 MHz ultrasound. We started with the ultrasound intensity of 1 W/cm<sup>2</sup>, which was later increased to 2 W/cm<sup>2</sup>. The duration of an ultrasound session was 8 minutes and it was applied to the places on the penis where the hard fibrous tissue was palpable. The patient received 3 treatments consisting of 30 visits with a 4 week period in between each of the two treatments. The cumulative number of visits was 90. After the last session we performed the diagnostic ultrasound again and calculated the change in plaque volume compared to the starting measurements. The patient also filled in the IIEF-5 questionnaire again.

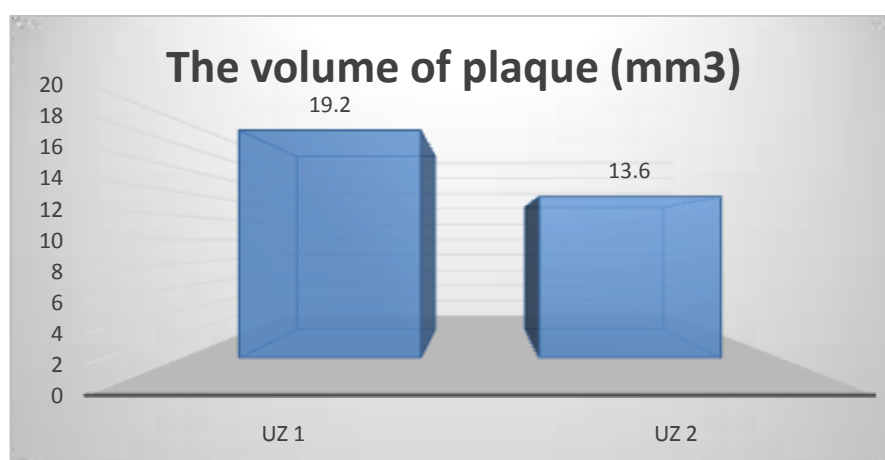
For about 18 months before the urologists referred him to us, the 49-year old patient had problems with his erections due to his penis being bent. When examined he reported an approximately 20 degree left sided bent

of the penis as well as incomplete penile filling during erection (hourglass). During erection pain was present and evaluated to be 7 on the visual analogue scale (VAS). While the penis was not in erection pain was absent. The patient reported problems holding the penis erect in its' distal part, the curvature posed no problem for him. The examination also showed a palpable fibrous tissue a few centimetres in length located on the right lateral side of the penis. A diagnostic ultrasound was performed both before ultrasound massage and after the end of the treatment protocol. Before treatment the ultrasound showed 2 mm big area with calcinations 1.6 mm x 6 mm and after treatment the area was the same but only hard tissue without calcinations was seen (4.7 mm long and 1.4 mm wide).. The angle of the curvature was not changed after the treatment. The results of IIEF-5 the patient filled out are shown in Fig 1. The result before the treatment showed 10 points and after the treatment 18 points. The change in plaque volume is shown in Fig 2. After the end of the third treatment the patient reported a subjective improvement, the pain was not present during erection and he believed that erectile function was improved as well.

### III. FIGURES



**Fig 1.** The results of International Index of Erectile function 5 (IIEF-5)



**Fig 2.** Changes of the plague volume

### IV. Discussion

Peyronie's disease is often accompanied by pain, deformity of the penis, erectile dysfunction and patient distress. It has been determined that some of the symptoms abate with time, especially pain. <sup>1-13</sup> Some also describe the plaque decreases in size.<sup>1-13</sup>

A more problematic difficulty is penile deformity, which often doesn't decrease and has a negative effect on sexual function. The patient develops psychological problems and depression, which gets worse as the years progress. <sup>1</sup> Because of how the penis looks men are often worried, which has a negative effect on self-image and sexuality – the fear of sexuality is increased and confidence plummets.

Usually the disease is first presented by a sudden visible curvature of the penis during erection, accompanied sometimes by mild pain. Often patients do not recall what caused the problem. Due to the curvature/deformity sexual intercourse is made difficult if not impossible. The diagnosis is made clinically, while a diagnostic ultrasound is needed as a follow up to assess the effectiveness of treatment. Since the disease has an important impact on the quality of life its' assessment is advised. For this we use the standardized questionnaires, the one

mentioned most often being International Index of Erectile Function' or it's shorter version.<sup>9</sup> In Slovenia patients with Peyronie's disease are treated by urologists. The type of therapy is based on the problems the patient exhibits. Different therapeutic procedures are also possible, but these lack evidence proving their effectiveness.<sup>1</sup> Different types of physical therapy can be used during a conservative treatment approach. We use iontophoresis, where by using electrical current we try to increase transcutaneous absorption of applied local drugs (such as verapamil or a combination of verapamil and dexamethasone). Studies have shown this combined therapy to be more effective than applying verapamil alone.<sup>1</sup> In the literature the use of ESWL (extracorporeal shock wave therapy) – a safe and effective method – is also described, however more studies are needed to prove it is effective.<sup>16</sup> Therapeutic ultrasound is used in the field of physical medicine for many years with research about its biological effect dating as far back as 1927.<sup>17</sup> Peyronie's disease is listed as an indication for the use of therapeutic ultrasound, however our review of the available literature did not find any research that would deal with the effect of this therapy on plaque size or disease progress.<sup>17</sup>

In our institution patients with Peyronie's disease are being treated with ultrasound therapy for almost 30 years. Even though the effects of this therapy are empirically good, they were never objectivised. By using a meticulously developed protocol which also encompasses objective follow up of plaque changes as well as quality of life assessment we managed to document positive effects of this non-invasive method of treatment in the afore mentioned case. The size of the plaques decreased and therefore their volume. The developed protocol is also being used in other patients receiving this therapy.

The used questionnaire IIEF-5 is a good tool to assess erectile dysfunction. It is short and simple; however the answers can be extremely subjective and can be affected by the ability of an individual to realistically answer the questions.

Our patient's results showed an increase in point summation; however he failed to achieve 20 points which would indicate an objective return to normal erectile function. Still the increase in the point summation correlates with the subjective feeling of improvement the patient reported. We also noticed that to make sure the answers to the questionnaire are realistic the presence of a medical worker is required; in our case this was the physiotherapist that conducted the therapy.

## V. Conclusion

The purpose of our paper is to highlight the possibility of using an additional conservative method in the treatment of Peyronie's disease. Ultrasound therapy is a time-consuming treatment where the effect is not guaranteed yet it is non-invasive and not uncomfortable. Despite the uncertainty of success we can assume men are ready to come to therapy which shows the disease has a negative effect on their emotional state. To establish the ultrasound therapy as a pillar for treating Peyronie's disease more well planned studies need to be performed since such studies have not yet been made.

## References

- [1]. Nehra A, Alterowitz R, Culkin DJ, et al. Peyronie's Disease: AUA Guideline. *J Urol* 2015; 194 (3): 745-753.
- [2]. Mulhall JP, Creech SD, Boorjian SA, et al. Subjective and objective analysis of the prevalence of Peyronie's disease in a population of men presenting for prostate cancer screening. *J Urol* 2004; 171: 2350.
- [3]. Taylor FL, Levine SD. Peyronie's disease. *Urol Clin North Am* 2007; 34: 517.
- [4]. Rosen R, Catania J, Lue T, et al. Impact of Peyronie's disease on sexual and psychosocial functioning; qualitative findings in patients and controls. *J Sex Med* 2008; 5: 1977.
- [5]. Smith JF, Walsh TJ, Conti SL, et al. Risk factors for emotional and relationship problems in Peyronie's disease. *J Sex Med* 2008; 5: 2197.
- [6]. Breyer BN, Shindel AW, Huang YC, Eisenberg ML, Weiss DA, Lue TF, Smith JF: Are sonographic characteristics associated with progression to surgery in men with Peyronie's disease. *J Urol* 2010; 183 (4): 1484-1488.
- [7]. Levine LA, Greenfield JM. Establishing a standardized evaluation of the man with Peyronie's disease. *International Journal of Impotence Research* 2003; 15 (5): S103-S112.
- [8]. Felipetto R, Vigano L, Pagni GL, Minervini R. Laser and ultrasonic therapy in simultaneous emission for treatment of plastic penile induration. *Minerva Urol Nefrol* 1995; 47 (1): 25-9.
- [9]. Rosen RC, Riley A, Wagner G, et al. The international Index of erectile function (IIEF): a multidimensional scale for assessment of erectile dysfunction. *Urology* 1997; 49: 822-830.
- [10]. Zihel S, Mihelič M, Oblak C, Ravnik – Oblak M. Potrditev veljavnosti prevoda mednarodnega indeksa erektilne funkcije. *ISSI* 1999 8 3 44 – 6 <http://www.mf.uni-lj/isis99-03/html/zihel44.html#1>
- [11]. Rosen RC, Cappelleri JC, Smith MD, Lipsky J, Pena BM. Development and evaluation of an abridged, 5-item version of the International Index of erectile function (IIEF-5) as a diagnostic tool for erectile dysfunction. *International journal of Impotence Research* 1999; 11: 319-326.
- [12]. Rosen RC, Althof SE, Giuliano F. Research instruments for the diagnosis and treatment of patients with erectile dysfunction. *Urology* 2006; 68 (3): 6-16.
- [13]. Staerman F, Pierrevelcin J, Ripert T, Menard J. Medium – term follow up of plaque incision and porcine small intestinal submucosal grafting for Peyronie's disease. *Int J Impot Res* 2010; 22 (6): 343 – 8.

- [14]. Nelson CJ, Diblasio C, kendirci M, Hellstrom W, Guhring P, Mulhall JP. The chronology of depression and distress in men with Peyronie's disease. *J Sex Med* 2008; 5 (8): 1985-90.
- [15]. Pires J, Travis M, Ellsworth P. Peyronie's disease: Overview and recent treatment advances. *Urol Nurs* 2015; 35 (4): 164-78.
- [16]. Neimark AI, Astakhov IuI, Sidor MV. Extracorporeal shock-wave therapy in the treatment of Peyronie's disease. *Urologiia* 2004; 2: 33-5.
- [17]. Mihelčič B. Uporaba ultrazvoka v fizikalni terapiji. V: Štefančič M (ur.). *Osnove fizikalne medicine in rehabilitacije gibalnega sistema*. Ljubljana: DZS, 2003, str. 135 – 141.